

Arthroprosthetic Cobaltism: Neurological and Cardiac Manifestations in Two Patients with Metal-on-Metal Arthroplasty

A Case Report

By Stephen S. Tower, MD*

Investigation performed at the Anchorage Fracture and Orthopedic Clinic, Anchorage, and the Alaska WWAMI Biomedical Program, Anchorage, Alaska

Early failure of metal-on-metal hip arthroplasties is a current concern because tissue damage resulting from periprosthetic metallosis can compromise subsequent revision arthroplasty^{1,2}. The United Kingdom's Medicines and Healthcare products Regulatory Agency has advised that patients with metal-on-metal implants who have pain, prosthetic malposition, or implants that are known to have excessive failure rates should be evaluated with the measurement of serum cobalt. A serum cobalt level of $>7 \mu\text{g/L}$ indicates possible periprosthetic metallosis^{3,4}. A normal serum cobalt level is $0.19 \mu\text{g/L}$, and 95% of those who are unexposed to cobalt have a value of $<0.41 \mu\text{g/L}$ ⁵. A serum cobalt level of $>1 \mu\text{g/L}$ indicates excessive cobalt exposure, and levels of $>5 \mu\text{g/L}$ are considered toxic⁶.

In excess, cobalt blocks cellular metabolism and can damage multiple organs. Cobalt poisoning (cobaltism) from beer additives, industrial exposure, or medicinal use is well known. Cobaltism can result in tinnitus, vertigo, deafness, blindness, optic nerve atrophy, convulsions, headaches, peripheral neuropathy, cardiomyopathy, and hypothyroidism^{7,8}. Including the two cases in the present report, there are at least six case reports of cobaltism related to arthroplasty implants (arthroprosthetic cobaltism)^{7,9-12}. These four patients presented with combinations of deafness, blindness, cognitive decline, headaches, convulsions, fatigue, weakness, peripheral neuropathy, heart failure, and hypothyroidism. All of these patients had periprosthetic metallosis due to wear of steel femoral heads by ceramic, and all had a serum cobalt level of $>60 \mu\text{g/L}$. The two cases described in the present report were included in a summary paper by the author and are the first cases of arthroprosthetic cobaltism attributed to metal-on-metal implants that could be identified⁷.

Case Reports

Both of the patients were fit, well, forty-nine-year-old men at the time of metal-on-metal arthroplasty with Articular

Surface Replacement implants (ASR; DePuy, Warsaw, Indiana). In one of the patients (Case 1), the index hip arthroplasty was performed elsewhere and the revision arthroplasty was performed by one of the author's partners. In the other patient, the index and revision arthroplasties were performed by the author. Both of these patients were briefly reported on in the State of Alaska Epidemiology Bulletin¹³, and are included in a review paper by the author on arthroprosthetic cobaltism⁷.

CASE 1. Metal-on-metal hip replacement was performed for the treatment of osteoarthritis. The shell and femoral head diameters were 60 and 53 mm, respectively. Acetabular inclination measured 54° on a frontal hip radiograph, and anteversion appeared excessive on a lateral hip radiograph (Fig. 1-A). The patient demonstrated improvement initially but developed progressive hip pain with activity. At three months postoperatively, axillary rashes were noted, although skin patch testing and a lymphocyte transformation assay showed no reactivity to cobalt or chromium. Eleven months after surgery, dyspnea and progressive hip pain were noted, imaging studies showed a large periprosthetic fluid collection, and the serum cobalt level was $50 \mu\text{g/L}$. At eighteen months, anxiety, headaches, irritability, fatigue, tinnitus, and hearing loss were noted; an audiogram demonstrated high-frequency hearing loss; and the serum cobalt level was $35 \mu\text{g/L}$. At thirty months, pain at rest, hip creaking, hand tremor, incoordination, cognitive decline, and depression were noted. At thirty-six months, visual changes were noted, optic nerve atrophy was found, and the serum cobalt level was $122 \mu\text{g/L}$.

Forty-three months after the initial arthroplasty, revision arthroplasty was done. Laboratory findings included a serum cobalt level of $83 \mu\text{g/L}$, a cerebrospinal fluid cobalt level of $2.2 \mu\text{g/L}$, and a joint fluid cobalt level of $3200 \mu\text{g/L}$. Diasystolic dysfunction was found on interval echocardiography. The pathologist noted metallosis, necrosis, and lymphocytic infiltrates.

Disclosure: The author did not receive any outside funding or grants in support of his research for or preparation of this work. Neither he nor a member of his immediate family received payments or other benefits or a commitment or agreement to provide such benefits from a commercial entity.

*EDITOR'S NOTE: It should be noted that one of the patients in the present study (Case 1) is the author of the report (S.S.T.).

Wear of the liner was estimated with use of several independent measures, including (1) the differential thickness of the liner rim at the worn and unworn quadrants as measured with use of a dial caliper (accuracy, ± 0.001 in [0.025 mm]), (2) the use of image analysis software to evaluate three-dimensional digital images of the liner rim geometry at the worn and unworn quadrants, and (3) a roundness measurement based on a circular scan around the articular surface of the liner 1 mm down from the rim (6000 Geometry Gage; Mahr Federal, Providence, Rhode Island).

Estimates of the depth of wear at the most worn quadrant of the liner were $400 \mu\text{m}$ (on the basis of differential rim thickness), $306 \mu\text{m}$ (on the basis of analysis of the images of the rim), and $381 \mu\text{m}$ (on the basis of out-of-roundness excursion) (Fig. 1-B).

Sequential roundness scans down into the liner indicated maximum wear at the rim, with wear depth diminishing to nearly zero at approximately 20° down into the liner. The general shape of the wear area was depicted in a computer-aided design (CAD) model that was generated to geometrically model the head-to-liner placement that would create the observed wear zone and

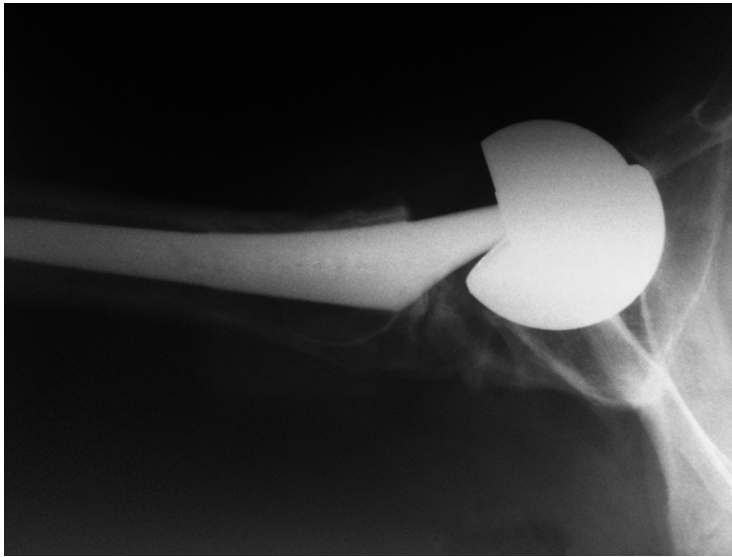


Fig. 1-A




Fig. 1-B

Figs. 1-A through 1-D Case 1. **Fig. 1-A** Cross-table lateral radiograph of the hip, showing excessive acetabular shell anteversion. **Fig. 1-B** Three-dimensional digital image of the liner rim at an unworn quadrant (left) and the worn quadrant (right) (VHX 1000E; Keyence, Woodcliff Lake, New Jersey). The as-manufactured radius between the articular surface and the rim shelf is apparent in the unworn quadrant but is completely worn through in the worn quadrant, leaving a sharp rim edge. Image analysis demonstrated that the rim dimension indicated by the arrows was $2129 \mu\text{m}$ at the unworn quadrant and $1823 \mu\text{m}$ in the worn quadrant, a difference of $306 \mu\text{m}$.

depth (Fig. 1-C). The wear zone shown in the figure is the volume of interference between the head and the liner generated by the head subluxating out of the liner by 1.0 mm and then translating laterally 0.3 mm.

The retrieved femoral head showed multiple burnished areas. The largest was in the peripolar area, was shaped like and sized proportionally to the polar ice cap, and, on magnified view, consisted primarily of fine parallel scratches (Fig. 1-D).

Eleven months after revision, the patient's hip pain, affect, cognition, hearing, exercise tolerance, tremor, and professional productivity were improved. His tinnitus and visual symptoms were stable. He had had five prosthetic dislocations, including one

that was self-reduced, two that were reduced by family members, and two that were reduced under general anesthesia.

CASE 2. Metal-on-metal hip replacement was performed for the treatment of a failed resurfacing of the femoral head. A 56-mm acetabular shell and a 49-mm femoral head were used, and an intraoperative radiograph confirmed the recommended implant position. One year after revision surgery, cognitive decline, vertigo, hearing loss, groin pain, rashes, and dyspnea were noted, and the serum cobalt level was 23 $\mu\text{g/L}$.

The hip was revised again forty months after the previous revision arthroplasty, at which time the serum cobalt level was




Fig. 1-C



Fig. 1-D

Fig. 1-C Computer-aided design (CAD) rendering of the hip with the head displaced axially outward by 1.0 mm and then shifted laterally in the plane of the liner rim by 0.3 mm (SolidWorks, Concord, Massachusetts). The shaded region indicates the interference that would occur with this head-liner position. **Fig. 1-D** *Left:* Macroscopic image of the head, with white draping to minimize reflection contrast. The boundaries of the wear zone on the head appear as darker bands. *Right:* Higher-magnification image of a segment of the wear zone boundary ($\times 150$).

23 µg/L and the joint fluid cobalt level was 3300 µg/L. Gross metallosis was noted on pathological examination, and the pseudocapsule was notably acellular (mature) fibrous tissue; no notable lymphocytic infiltrates could be identified. The acetabular shell showed scratching but no visible eccentricity. The femoral head had an equatorial wear scar. Seven months following the last revision arthroplasty, the patient demonstrated improvement but had required one hip reduction under sedation.

Discussion

The patients described in the current report, like those described in previous case reports on arthroprosthetic cobaltism, presented with hip pain resulting from periprosthetic metallosis as well as neurological and cardiac symptoms resulting from elevated serum cobalt. All patients demonstrated improvement after revision. One of the patients (Case 1) had a cerebrospinal fluid cobalt level that was seventeen times normal¹⁴. Similarly elevated cerebrospinal fluid levels of cobalt were noted in two previously reported cases of neurological arthroprosthetic cobaltism^{9,11}.

The pattern of wear of the bearing in the first patient (Case 1) was consistent with edge loading due to prosthetic malposition¹⁵. The annualized wear rate of 100 µm was 100-fold that of metal-on-metal bearings revised for reasons other than metallosis¹⁶. The wear pattern of the bearing in the other patient (Case 2) suggested inadequate bearing clearance¹⁷.

A serum cobalt level of >20 µg/L is common in patients with an ASR implant with prosthetic malposition or with a femoral head diameter of <50 mm¹. Patients with other types of metal-on-metal hips also can have a serum cobalt level of >20 µg/L. In a series of 214 patients with different hip resurfacing implants, ten patients had a serum cobalt level of ≥20 µg/L and one patient had a value of 111 µg/L¹⁸.

In the patients described here, the revision arthroplasties were complicated by instability, a complication that has been reported to occur more frequently in hips that are revised because of metallosis¹⁹.

Very high serum cobalt levels can occur in patients with well-positioned 28-mm metal-on-metal bearings if renal function is impaired²⁰. These patients might develop cobaltism without sentinel hip pain. Many patients with metal-on-metal hip implants may develop renal impairment with time. Coresh et al. reported that 43% of American adults between forty and fifty-nine years of age and 74% of those more than seventy years of age have acquired impaired renal function²¹.

Metal-on-metal hips have become popular over the past decade. In a sample of 112,095 hip arthroplasties performed in the United States from October 2005 to December 2006, 35% involved the use of metal-on-metal bearing surfaces²².

Cardiac and neurological impairments are endemic in older patients undergoing hip arthroplasty. A study of a large group of patients with metal-on-metal implants will be required to define the prevalence and spectrum of arthroprosthetic cobaltism.

Patients with metal-on-metal hips are at risk for cobaltism if the bearings wear excessively or if renal function declines. Most patients with metal-on-metal implants have higher serum cobalt levels than industrial workers and may be at risk for subclinical cognitive²³ and cardiac²⁴ impairment. A serum cobalt level of >20 µg/L is common in some groups of patients with metal-on-metal implants^{18,25} and may result in symptomatic neurological and cardiac cobaltism^{7,13}. Severe neurological and cardiac impairments have been reported in association with arthroprosthetic cobaltism when serum cobalt exceeds 60 µg/L^{7,9-13}.

The patients with metal-on-metal hip implants who are at the highest risk for cobaltism are those with shell malposition or persistent hip pain^{3,7,13}, those with renal impairment²⁰, and those with ASR implants^{7,13,25}. Serum cobalt should be measured in these patients. Neurological and cardiac assessments should be considered for patients with a serum cobalt level of ≥7 µg/L^{7,13}. Revision arthroplasty should be considered for patients with periprosthetic metallosis and those with neurological or cardiac impairments temporally linked to elevated serum cobalt levels^{4,7,13}.

Surgeons need to be aware that the high serum cobalt levels found in some patients with metal-on-metal hips may cause neurological or cardiac damage that is in part reversible with timely revision surgery. ■

Note: J.H. Currier, MS, and D.J. McHugh of the Dartmouth Biomedical Engineering Center at the Thayer School of Engineering performed the analysis of the explanted bearing of one of the patients (Case 1). Dr. Thomas Meigo of the Providence Alaska Medical Center reviewed the pathology of both cases and organized the cobalt analyses. Dr. Thomas Vasileff of the Anchorage Fracture and Orthopedic Clinic confirmed the accuracy of the report of Case 1 (the author). Dr. John Sotos of the University of North Carolina assisted the author with the nosology of cobalt poisoning and in the naming of the syndrome "arthroprosthetic cobaltism."

Stephen S. Tower, MD
Anchorage Fracture and Orthopedic Clinic,
Suite 200, 3260 Providence Drive,
Anchorage,
AK 99508.
E-mail address: tower@afoc.com

References

- Langton DJ, Jameson SS, Joyce TJ, Hallab NJ, Natsu S, Nargol AV. Early failure of metal-on-metal bearings in hip resurfacing and large-diameter total hip replacement: a consequence of excess wear. *J Bone Joint Surg Br.* 2010;92:38-46.
- Malviya A, Holland JP. Pseudotumours associated with metal-on-metal hip resurfacing: 10-year Newcastle experience. *Acta Orthop Belg.* 2009;75:477-83.
- Medicines and Healthcare products Regulatory Agency (MHRA). Medical device alert: all metal-on-metal (MoM) hip replacements (MDA/2010/033). 2010 Apr 22. <http://www.mhra.gov.uk/Publications/Safetywarnings/MedicalDeviceAlerts/CON079157>. Accessed 2010 Oct 18.
- De Smet K, De Haan R, Calistri A, Campbell PA, Ebramzadeh E, Pattyn C, Gill HS. Metal ion measurement as a diagnostic tool to identify problems with metal-on-metal hip resurfacing. *J Bone Joint Surg Am.* 2008;90 Suppl 4:202-8.
- Alimonti A, Bocca B, Mannella E, Petrucci F, Zennaro F, Cotichini R, D'Ippolito C, Agresti A, Caimi S, Forte G. Assessment of reference values for selected element in a healthy urban population. *Ann Ist Super Sanita.* 2005;41:181-7.
- Leavelle DE, editor. Mayo Medical Laboratories interpretive handbook: interpretive data for diagnostic laboratory tests. Rochester, MN: The Laboratories; 2001.

- 7.** Tower SS. Arthroprosthetic cobaltism: identification of the at-risk patient. *Alaska Medicine*. 2010;52:28-32.
- 8.** Smith HIC, Carson BL. Trace metals in the environment. Volume 6: cobalt. An appraisal of environmental exposure. Ann Arbor, MI: Ann Arbor Science; 1981.
- 9.** Steens W, von Foerster G, Katzer A. Severe cobalt poisoning with loss of sight after ceramic-metal pairing in a hip—a case report. *Acta Orthop*. 2006;77:830-2.
- 10.** Oldenburg M, Wegner R, Baur X. Severe cobalt intoxication due to prosthesis wear in repeated total hip arthroplasty. *J Arthroplasty*. 2009;24:825.e15-20.
- 11.** Rizzetti MC, Liberini P, Zarattini G, Catalani S, Pazzaglia U, Apostoli P, Padovani A. Loss of sight and sound. Could it be the hip? *Lancet*. 2009;373:1052.
- 12.** Ikeda T, Takahashi K, Kabata T, Sakagoshi D, Tomita K, Yamada M. Polyneuropathy caused by cobalt-chromium metallosis after total hip replacement. *Muscle Nerve*. 2010;42:140-3.
- 13.** Tower SS. Cobalt toxicity in two hip replacement patients. *State of Alaska Epidemiology Bulletin*. 2010 May 28. www.epi.hss.state.ak.us/bulletins/docs/b2010_14.pdf. Accessed 2010 Oct 19.
- 14.** Mitchell JD, Harris IA, East BW, Pentland B. Trace elements in cerebrospinal fluid in motor neurone disease. *Br Med J (Clin Res Ed)*. 1984;288:1791-2.
- 15.** Morlock MM, Bishop N, Zustin J, Hahn M, Rütger W, Amling M. Modes of implant failure after hip resurfacing: morphological and wear analysis of 267 retrieval specimens. *J Bone Joint Surg Am*. 2008;90 Suppl 3:89-95.
- 16.** Kwon YM, Glyn-Jones S, Simpson DJ, Kamali A, McLardy-Smith P, Gill HS, Murray DW. Analysis of wear of retrieved metal-on-metal hip resurfacing implants revised due to pseudotumours. *J Bone Joint Surg Br*. 2010;92:356-61.
- 17.** Malviya A, Ramaskandhan J, Holland JP, Lingard EA. Metal-on-metal total hip arthroplasty. *J Bone Joint Surg Am*. 2010;92:1675-83.
- 18.** De Haan R, Pattyn C, Gill HS, Murray DW, Campbell PA, De Smet K. Correlation between inclination of the acetabular component and metal ion levels in metal-on-metal hip resurfacing replacement. *J Bone Joint Surg Br*. 2008;90:1291-7.
- 19.** De Haan R, Campbell PA, Su EP, De Smet KA. Revision of metal-on-metal resurfacing arthroplasty of the hip: the influence of malpositioning of the components. *J Bone Joint Surg Br*. 2008;90:1158-63.
- 20.** Brodner W, Grohs JG, Bitzan P, Meisinger V, Kovarik J, Kotz R. [Serum cobalt and serum chromium level in 2 patients with chronic renal failure after total hip prosthesis implantation with metal-metal gliding contact]. *Z Orthop Ihre Grenzgeb*. 2000;138:425-9. German.
- 21.** Coresh J, Byrd-Holt D, Astor BC, Briggs JP, Eggers PW, Lacher DA, Hostetter TH. Chronic kidney disease awareness, prevalence, and trends among U.S. adults, 1999 to 2000. *J Am Soc Nephrol*. 2005;16:180-8.
- 22.** Bozic KJ, Kurtz S, Lau E, Ong K, Chiu V, Vail TP, Rubash HE, Berry DJ. The epidemiology of bearing surface usage in total hip arthroplasty in the United States. *J Bone Joint Surg Am*. 2009;91:1614-20.
- 23.** Jordan CM, Whitman RD, Harbut M. Memory deficits and industrial toxicant exposure: a comparative study of hard metal, solvent and asbestos workers. *Int J Neurosci*. 1997;90:113-28.
- 24.** Linna A, Oksa P, Groundstroem K, Halkosaari M, Palmroos P, Huikko S, Uitti J. Exposure to cobalt in the production of cobalt and cobalt compounds and its effect on the heart. *Occup Environ Med*. 2004;61:877-85.
- 25.** Langton DJ, Sprowson AP, Joyce TJ, Reed M, Carluke I, Partington P, Nargol AV. Blood metal ion concentrations after hip resurfacing arthroplasty: a comparative study of articular surface replacement and Birmingham Hip Resurfacing arthroplasties. *J Bone Joint Surg Br*. 2009;91:1287-95.